

CASE REPORT

# Microcystic adnexal carcinoma of the centrofacial region: a case report

## *Carcinoma annessiale microcistico centrofaciale: presentazione di un caso*

G.A. BELTRAMINI, A. BAJ, L. MONEGHINI<sup>1</sup>, T. POLI<sup>2</sup>, V.A. COMBI, A.B. GIANNI

Department of Maxillo-Facial Surgery, University of Milan, IRCCS Istituto Ortopedico Galeazzi, Milan; <sup>1</sup> Department of Medicine, Surgery and Dentistry, Division of Pathology, University of Milan, San Paolo Hospital and Fondazione IRCCS Ospedale Maggiore Policlinico, Regina Elena e Mangiagalli, Milan; <sup>2</sup> Department of Maxillo-Facial Surgery, University of Parma, Parma Hospital, Italy

### SUMMARY

Microcystic adnexal carcinoma is a rare, locally aggressive neoplasm with both eccrine and follicular differentiation and a high probability of perineural invasion of the centrofacial region. Given the histopathological features of this tumour, early diagnosis is essential for adequate management. This report refers to a case of microcystic adnexal carcinoma of the nasogenial region, with infiltration of the deep planes extending to the anterior wall of the maxillary sinus. Surgical treatment involved wide demolition of the centrofacial region followed by reconstruction using four locoregional flaps: an Indian flap and a Mustardé flap were used for cutaneous reconstruction; a septal flap to support the maxillo-genial region; a mucosal flap to separate the nasal cavities.

KEY WORDS: Microcystic adnexal carcinoma • Mustardé flap • Forehead flap

### RIASSUNTO

*Il carcinoma annessiale microcistico è un tumore raro, localmente aggressivo, con spiccata tendenza all'infiltrazione perineurale che colpisce soprattutto la cute della regione centro facciale. Viste le caratteristiche istopatologiche, la diagnosi precoce di questa neoplasia è essenziale per un adeguato trattamento. Gli Autori descrivono un caso di carcinoma eccrino microcistico della regione naso-geniena, infiltrante i piani profondi sino alla parete anteriore del seno mascellare. Il trattamento chirurgico della neoplasia ha previsto un'ampia demolizione della regione centro facciale e successiva ricostruzione mediante l'utilizzo di 4 lembi locoregionali: il lembo indiano e il lembo di Mustardé utilizzati per la ricostruzione cutanea, un lembo settale per il sostegno della regione maxillo-geniena ed un lembo mucoso per dividere nuovamente le due cavità nasali.*

PAROLE CHIAVE: *Carcinoma annessiale microcistico • Lembo di Mustardé • Lembo frontale*

Acta Otorhinolaryngol Ital 2010;30:213-216

Microcystic adnexal carcinoma (MAC) is a rare eccrine gland tumour with low-grade malignancy and a low probability of metastasis. It generally affects the centrofacial region in older individuals. A characteristic histological feature is epithelial proliferation that progressively involves microcysts, strands, and cords as the tumour invades the deeper tissues from the skin surface. It has a severe tendency to neurotropic spread and presents with widely infiltrated margins. These characteristics make demolition surgery, especially in the centro-facial region, particularly challenging<sup>1-4</sup>.

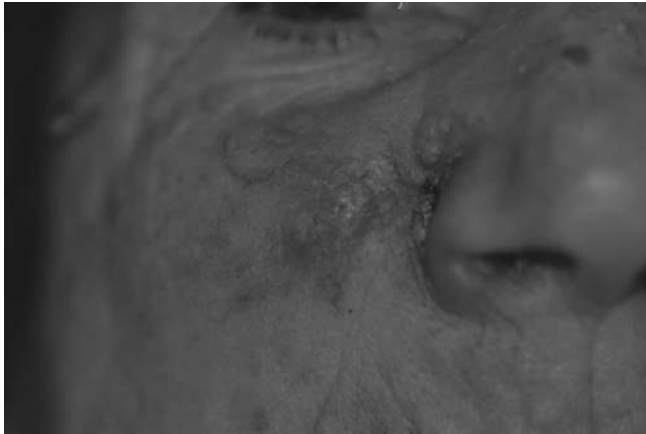In this report, a case is presented of MAC of the centrofacial region, with involvement of the deep planes extending to the anterior wall of the maxillary sinus. The tumour was excised with wide demolition which was reconstructed using 4 local flaps: 2 chondro-mucosal flaps and 2 fas-

cio-cutaneous flaps for skeletal support and restoration of the facial integument with good matching of skin colour.

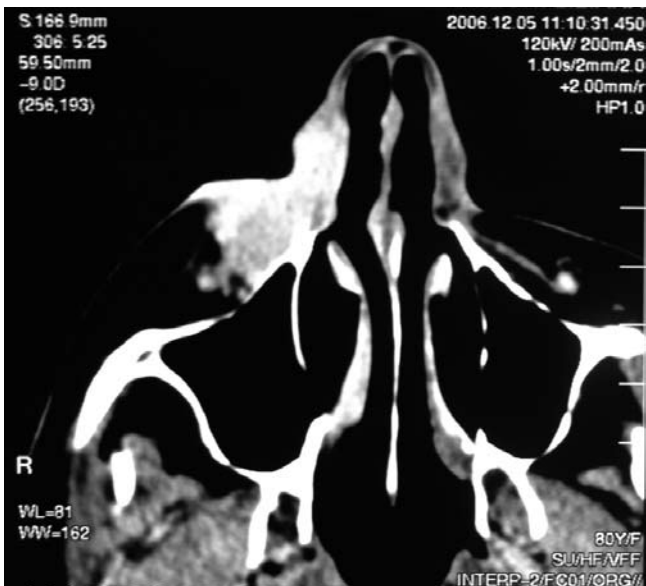
### Case report

In January 2007, an 81-year-old female was seen for an extensive, hard-rubbery neoplasm (~3 cm in diameter) fixed to the deep planes and involving the *ala nasi* and right nasogenial sulcus (Fig. 1). The case history revealed that a basalioma of the right genial region, arising in a setting of actinic keratosis, had been removed several years previously.

Contrast computed tomography (CT) and magnetic resonance imaging (MRI) revealed a neoplasm involving the naso-genial region, *ala nasi*, and right lip, with infiltration into the deep planes towards the anterior wall of the max-



**Fig. 1.** An 81-year-old female with a large, hard-rubbery neoplasm involving ala nasi and right naso-genial sulcus.



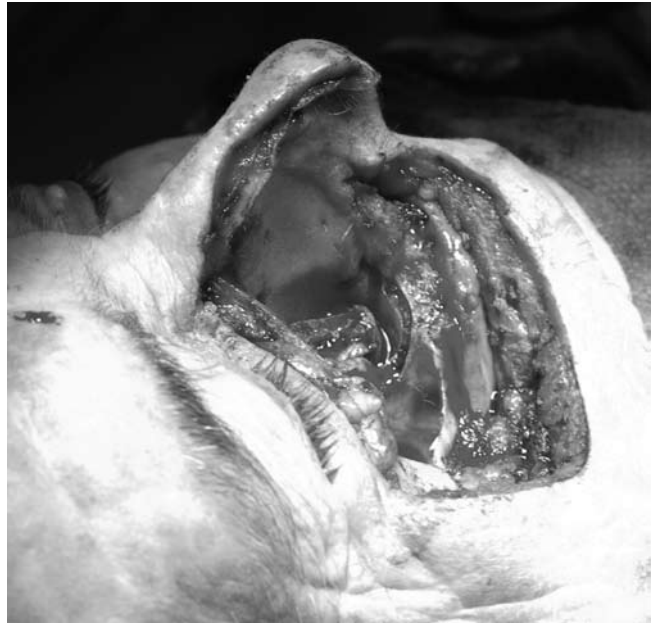**Fig. 2.** Pre-operative contrast CT shows neoplasm involving naso-genial region, ala nasi, and right lip, with infiltration into deep planes towards anterior wall of maxillary sinus, without invading the sinus.

illary sinus, without actually invading the sinus (Fig. 2). A biopsy specimen demonstrated the epithelial origin of the lesion and its proliferative nature.

Surgery included demolition of the right half of the nasal pyramid to the cartilage septum and part of the right nasal bone, with excision of the cheek skin and anterior wall of the maxillary sinus to the orbital rim, molar pillar, alveolar crest, and lip skin (Fig. 3).

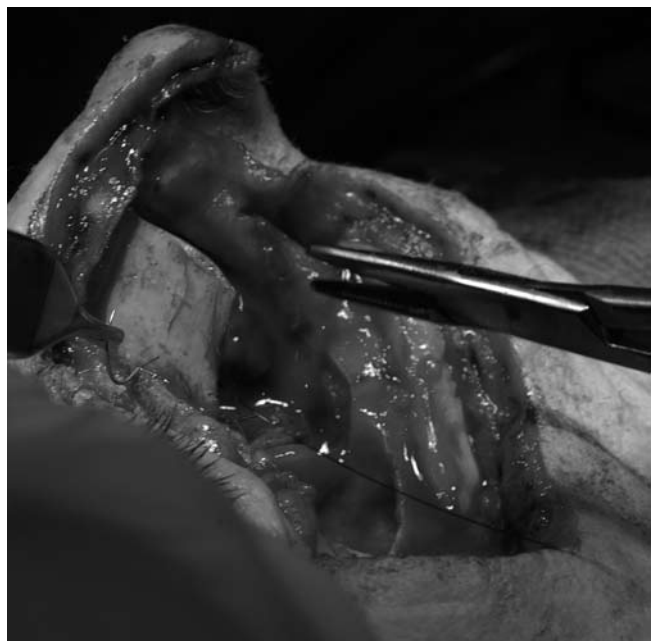
Intra-operative frozen section analysis of the resection margins and the infra-orbital nerve was performed.

Reconstruction was carried out using a fasciocutaneous cheek advancement (Mustardé) flap<sup>2</sup> to restore the aesthetic subunit of the cheek. The nasal pyramid was reconstructed using a left para-median forehead flap<sup>3</sup> rotated 180° to restore the half dorsum, tip of the nose, and *ala nasi*. Cutaneous lining was achieved with a flip-flap harvested from



**Fig. 3.** Intra-operative view: demolition involved right half of nasal pyramid to cartilage septum and part of right nasal bone, with excision of cheek skin and anterior wall of maxillary sinus to orbital rim, molar pillar, alveolar crest, and lip skin.

the septum (Fig. 4). A superiorly pedicled flap, composed of septal cartilage and mucosa of the septum contralateral to the lesion, was rotated and sutured to the orbital rim to support the skin flaps; an inferiorly pedicled flap composed of the septal mucosa of the affected side was fashioned to create a septum to separate the nasal cavities (Figs. 5, 6).



**Fig. 4.** Flip-flap harvested from septum. A superiorly pedicled flap composed of septal cartilage and mucosa of septum was rotated and sutured to orbital rim; an inferiorly pedicled flap composed of septal mucosa was fashioned to separate nasal cavities.

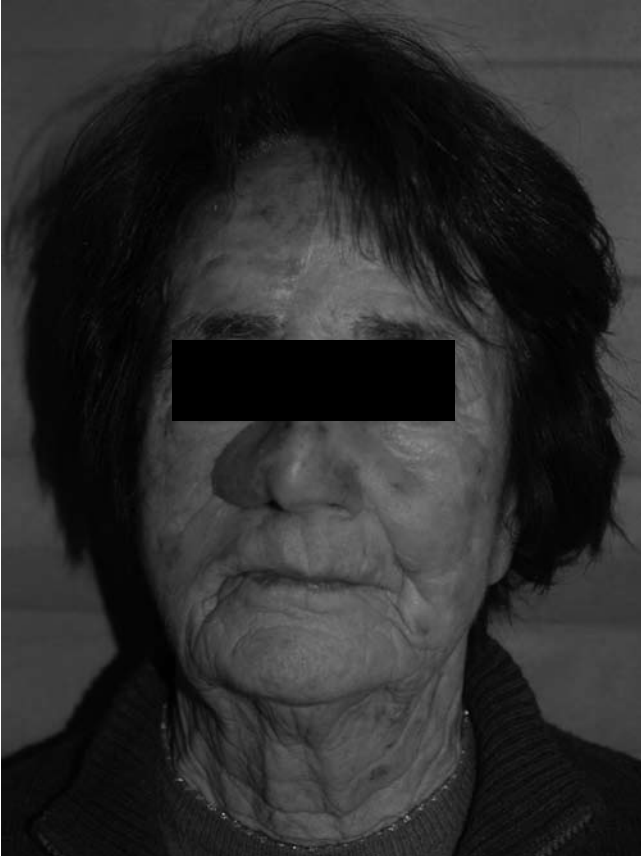

Fig. 5. Post-operative view: 1-year follow-up.

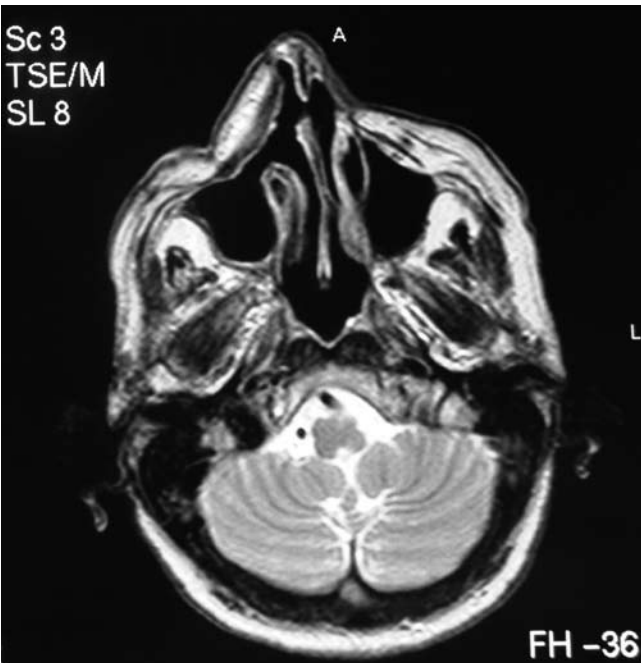


Fig. 6. Post-operative RMN.

Macroscopic examination showed contraction of the upper lip (1.4 cm in diameter); on incision, a hard-rubbery neoplasm with indistinct margins was observed in the der-

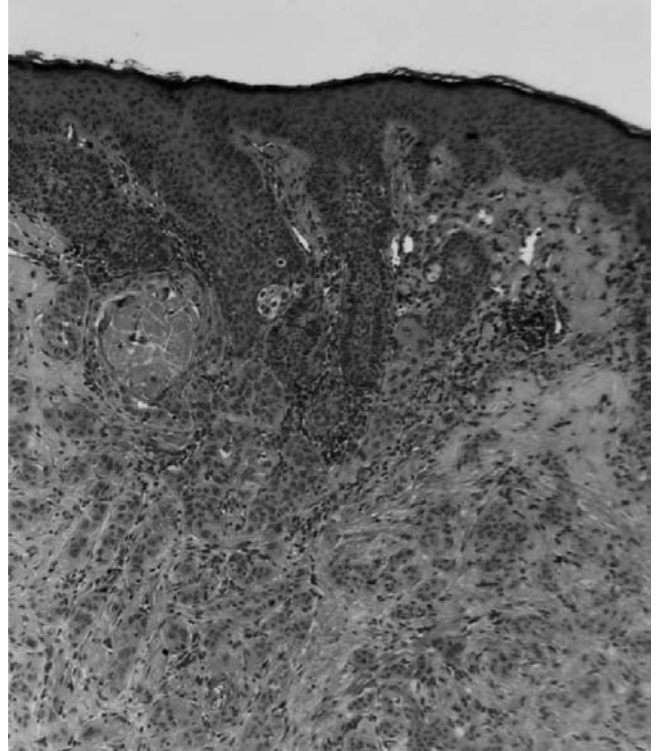


Fig. 7. Uppermost part of MAC with micronests, solid cord and keratinic cysts (10X; H&H).

mohypodermal layer, with infiltration of the soft tissues extending to the maxillary bone.

Histopathological examination of the uppermost part of the reticular derma showed the proliferation of micronests and solid cords consisting of mildly atypical monomorphous cuboid cells embedded in an abundant desmoplastic stroma alternating with keratinic cysts (Fig. 7). In the deeper plane, there were ductal structures with two layers of cuboid epithelial cells gradually replaced by microcysts and prevalently neurotropic monofilament cords (Fig. 8). Based on the histologic features, a

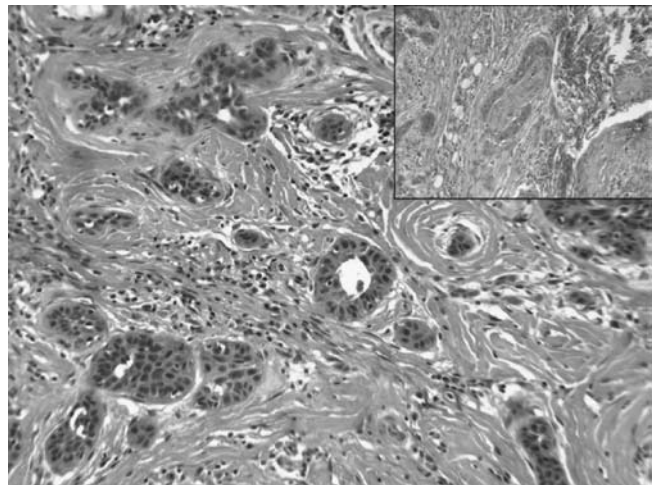


Fig. 8. Deeper part of MAC with involvement of ductal structures and nerves (inset) (25X; H&H).

diagnosis of MAC with eccrine differentiation was established.

The differential diagnosis included several other neoplasms: benign adnexal tumours (syringoma and desmoplastic trichoepithelioma), locoregional malignant tumours (malignant mixed tumour of skin appendages, sclerodermiform basal cell carcinoma of the skin, and neoplasms of the minor salivary glands), and metastasis of carcinomas occurring elsewhere, such as breast cancer<sup>4</sup>.

## Discussion

The classification of cutaneous adnexal tumours, especially eccrine tumours, continues to give rise to difficulties on account of the number of adnexal tumours variously identified and the variety of names used to describe them<sup>5</sup>. The basic organising principle is to classify adnexal tumours according to histologically distinguishable differentiation (follicular, sebaceous, apocrine, and eccrine) and their degree of maturity (hamartoma, adenoma, benign, primitive, and malignant)<sup>6</sup>. Once thought to be derived from mature adnexal cells, rather than via the transformation of genetically altered skin cells, the current most-accredited hypothesis is that adnexal tumours

arise from adnexal differentiation of pluripotent cutaneous stem cells. This explains why some adnexal tumours can present concomitantly with three different modes of differentiation: pilosebaceous, eccrine, and apocrine<sup>7,8</sup>. Micro-cystic adnexal carcinoma is classified as a malignant neoplasm with prevalently eccrine differentiation, which in some cases manifests with pilosebaceous or apocrine differentiation<sup>9</sup>. Other names used in the histopathological diagnosis of this tumour are sclerosing sweat duct carcinoma, eccrine epithelioma, and syringomatous carcinoma.

Excision of the neoplasm requires wide tissue demolition, because of the wide resection margins necessary. Repairing the resulting defect poses a considerable reconstructive challenge, particularly in the centropalpebral region. While free flaps may meet tissue requirements, this cannot be said for their quality. In addition, as skin is lost due to the excision, reconstruction of the facial region with free flaps represents a limitation due to dyschromia after healing. Therefore, we chose local cutaneous, mucosal, and cartilage flaps to support the classic Mustardé and Indian flaps and to achieve an aesthetically acceptable outcome with more uniform facial skin chromatics<sup>10-12</sup>.

## References

- 1 Friedman PM, Friedman RH, Jiang SB, Nouri K, Amonette R, Robins P. *Microcystic adnexal carcinoma: collaborative series review and update*. J Am Acad Dermatol 1999;41:225-31.
- 2 Mustardé JC. *New horizons in eyelid reconstruction*. Int Ophthalmol Clin 1989;29:237-46.
- 3 Yalamanchili H, Sclafani AP, Schaefer SD, Presti P. *The path of nasal reconstruction: from ancient India to the present*. Facial Plast Surg 2008;24:3-10.
- 4 Goldstein DJ, Barr RJ, Santa Cruz DJ. *Microcystic adnexal carcinoma: a distinct clinicopathologic entity*. Cancer 1982;50:566-72.
- 5 Urso C, Anichini C. *Cancers of the sweat glands: problems and controversies at the end of the 20th Century*. Pathologica 2000;92:225-35.
- 6 Le Boit PE, Burg G, Weedon D, Sarasin A. *World Health Organization Classification of Tumours. Pathology and genetics of skin tumours*. Lyon: IARC Press; 2006.
- 7 Alsaad KO, Obaidat NA, Ghazarian D. *Skin adnexal neoplasms – Part 1: An approach to tumours of the pilosebaceous unit*. J Clin Pathol 2007;60:129-44.
- 8 Obaidat NA, Alsaad KO, Ghazarian D. *Skin adnexal neoplasms – Part 2: An approach to tumours of cutaneous sweat glands*. J Clin Pathol 2007;60:145-59.
- 9 Requena L, Marquina A, Alegre V, Aliaga A, Sanchez Yus E. *Sclerosing-sweat-duct (microcystic adnexal) carcinoma – a tumor from a single eccrine origin*. Clin Exp Dermatol 1990;15:222-4.
- 10 Sand M, Boorboor P, Sand D, Altmeyer P, Mann B, Bechara FG. *Bilateral cheek-to-nose advancement flap: an alternative to the paramedian forehead flap for reconstruction of the nose*. Acta Chir Plast 2007;49:67-70.
- 11 Heppt W, Gubisch W. *Principles of nasal defect repair*. HNO 2007;55:497-510.
- 12 Mazzola RF. *Reconstruction of the nose – a historical review*. Handchir Mikrochir Plast Chir 2007;39:181-188.

Received: May 27, 2009 - Accepted: September 4, 2009

Address for correspondence: Dr.ssa G.A. Beltramini, Divisione di Chirurgia Cervico-Facciale, Istituto Ortopedico Galeazzi – Università di Milano, Via Riccardo Galeazzi, 4, 20161 Milano, Italy. Fax: +39 02 66214770. E-mail: giada.beltramini@hotmail.it